

The severe Acute Hemorrhagic Necrotizing Encephalopathy in Infected COVID-19 patient

Sandio A^{1*}, Ajibola O², Ramakrishnan S⁴, Cadet PR¹, Apata M⁴, Dada S⁵, Asare S¹, Koumou C⁶, Tynes B⁷

¹Department of medicine, Wayne State University, USA

²Nuvance Health, Vassar Brothers Medical Center, USA

³Department of Medicine, Houston Healthcare Atlanta, USA

⁴Unity Hospital, Rochester Regional Health, USA

⁵Department of Medicine, Windsor University school of Medicine, USA

⁶Department of Medicine, Yaounde Central Hospital, USA

⁷Internal medicine & Pediatrics, Wayne State University & DMC hospital, USA

*Corresponding author:

Aubin Sandio, MD, MPH,
Internal Medicine Department, Detroit medical
center, Wayne State University,
USA, E-mail: asandio@med.Wayne.edu

Received: 13 Apr 2022

Accepted: 25 Apr 2022

Published: 30 Apr 2022

J Short Name: ACMCR

Copyright:

©2022 Sandio A. This is an open access article distributed under the terms of the Creative Commons Attribution License, which permits unrestricted use, distribution, and build upon your work non-commercially.

Citation:

Sandio A, The severe Acute Hemorrhagic Necrotizing Encephalopathy in Infected COVID-19 patient. Ann Clin Med Case Rep. 2022; V9(1): 1-3

1. Abstract

COVID-19 infection initiates a multi systemic inflammatory syndrome with various organ manifestations. Although respiratory symptoms are the most common presentation for COVID-19, neurological manifestations have still been reported, but with devastating outcomes. A 57-year-old male smoker was admitted with severe COVID-19. Active measures were undertaken to tackle the cytokine storm with Tocilizumab and Hydroxychloroquine, while providing ventilator support. However, patient developed AKI that required CRRT with heparin drip. On day 7 of hospitalization, patient acutely developed fixed dilated left pupil and CT brain revealed hemorrhagic necrosis of parenchyma. The purpose is to shed light on the pathophysiology behind AHNE, related to the disease activity and treatment. The aim of reporting this case is to sensitize clinicians on hemorrhagic necrotizing encephalopathy as a possible neurological complication of COVID-19 with severe cytokine storm.

2. Introduction

Acute necrotizing encephalopathy (ANE) has been reported as a rare complication of influenza and other viral infections with one case of AHNE related to COVID-19 reported. ANE is due to an intracranial cytokine storm resulting in a breakdown of blood-brain barrier without direct viral invasion or demyelination [1,2].

Cytokine storm syndrome with a resultant dysregulation of the blood-brain-barrier and direct viral-mediated endotheliopathy are the proposed mechanism of AHNE [3,4]. The most common presenting symptoms with SARS-CoV-2 infection are fever, malaise, headache, dyspnea, diarrhea, cough, and abdominal pain just to name a few [5,6]. Most patients have severe pulmonary manifestations leading to hypoxemic respiratory failure requiring intubation and mechanical ventilation with multiorgan dysfunction and cytokine storm [7,8]. Neurologic manifestations of coma and persistent encephalopathy dominated clinical presentation, followed by seizures and focal deficits [8].

3. Case Presentation

A 57-year-old man with history of chronic tobacco abuse and hypertension on lisinopril and metoprolol that presented with 7 days fever, cough, body aches and dyspnea. The vitals remarkable for respiratory rate 32 bpm and oxygen saturation 88% on 4L oxygen. There were scant rhonchi on lung examination. Labs remarkable for lymphopenia 800/mcL, hypoalbuminemia at 2.9, hypoxemia at 58. PaO₂/FiO₂ ratio was 174 mmHg. CXR showed patchy multifocal airspace opacities. The patient was started on ceftriaxone and azithromycin for pneumonia, however, he developed worsening respiratory failure and hypotension within few hours of admission requiring intubation and vasopressors for acute respiratory distress

syndrome (ARDS) and septic shock. The COVID-19 PCR came back positive and was started on hydroxychloroquine. The patient had persistent fever, decreasing PaO₂/FiO₂ ratio and significantly elevated inflammatory markers (ESR 85 mm/hr and CRP high-sensitive 268.37 mg/L), so tocilizumab was initiated for cytokine surge and after 2 doses, patient developed acute kidney injury requiring continuous renal replacement therapy (CRRT). The CRRT circuit clotted and patient was started on heparin drip. On day 7 of hospitalization, patient acutely developed fixed dilated left pupil. CT brain showed extensive multifocal parenchymal hemorrhages in the frontoparietal lobes, corpus callosum, basal ganglia, thalami with surrounding edema, intraventricular, subarachnoid and parafalcine subdural hemorrhage with a midline shift, suggestive of AHNE in the setting of COVID-19 and intracranial cytokine storm. Heparin was discontinued, and anticoagulation reversed. After extensive discussion with various subspecialists and patient's family, decision was made to pursue comfort measures and patient passed on hospital day 16.

4. Discussion

Frequently reported central nervous system manifestations of COVID-19 infections were all checked, screened before settling for Acute hemorrhagic necrotizing encephalitis (AHNE) as the diagnosis of choice for our patient. Our patient was negative for encephalitis, seizures, meningitis, ischemic and hemorrhagic stroke as well as persistent disorders of consciousness, sinus venous thrombosis, ataxia, just to name a few [9-11]. AHNE is a rare neurologic complication secondary to para-infectious and hyperimmune response to SARS-CoV-2 infection and is one of the rare complications affecting patients with severe COVID-19 infection. Our patient's signs and symptoms occurred between one to two weeks particularly following infection of the upper respiratory tract. Our patient had hemorrhagic necrosis of the parenchyma which is linked with high mortality rates. Characteristic findings on MRI of the brain in AHNE patients tends to show; symmetrical T2/FLAIR (T2-weighted/fluid-attenuated inversion recovery) with particularly hyperintense lesions focusing in areas of the subcortical white matter, cortex, thalami, basal ganglia image, brain stem, and cerebellar hemispheres, along with diffuse microhemorrhages

on susceptibility-weighted imaging [11,12] (Figure 1).

COVID-19 infection's neurotropism leads to devastating neurologic outcomes. Diagnosis requires a high index of suspicion in patients who have unexplained persistent severe encephalopathy associated with COVID-19 infection. Our patient with AHNE got administered dexamethasone, with or without immunomodulation therapies such as intravenous immunoglobulin, plasma exchange, or convalescent plasma. Our 57-year-old male patient had a history of tobacco abuse as well as hypertension and presented with 5 -7 days of high-grade fever, cough, body aches or myalgia and dyspnea. History of medical illness and noncompliance with medications could have played a huge role in disease progression to AHNE. About day 7-8, hypogeusia and hyposmia came in as new signs and symptoms. Despite quality management and close observation, patient showed little to no improvement and at day 12, with extensive discussions with various subspecialists and patient's family, a decision was made to pursue comfort measures and patient passed on hospital in the early hours just after 2:00 am on day 16. COVID-19 (SARS-CoV-2) is a primary respiratory pathogen that can proceed to CNS manifestations particularly with immunocompromised patients like ours. While it is pertinent to only discuss CNS signs and symptoms, medicine tends to operate in a holistic view point. That is a headache could be from abdominal pain or leg or ankle pain or even back pain. So carefully observing what goes on in the peripheral nervous system could serve as a good clue. In our case, it did. PNS manifestations included hyposmia, hypogeusia, neuropathy, myalgia, and polyradiculitis. When such happens, the route is pertinent. Potential routes of neurotropism and neuro-invasion entails retrograde axonal transport via olfactory nerve endings and/or taste buds [13,14] or brain invasion via hematogenous spread of the virus [15]. Patient's history of heavy tobacco intake and COPD could have led to acute respiratory distress syndrome (ARDS)/pneumonia leading to hypoxic CNS insult/damage [16] further causing a prothrombotic state secondary to endothelial damage [15]. Embolic events due to SARS-CoV-2-ACE2R-mediated vascular damage and disruption of the blood-brain-barrier (BBB) could also not be ruled out [17,18] particularly with excess bleeding when patient was administered heparin.

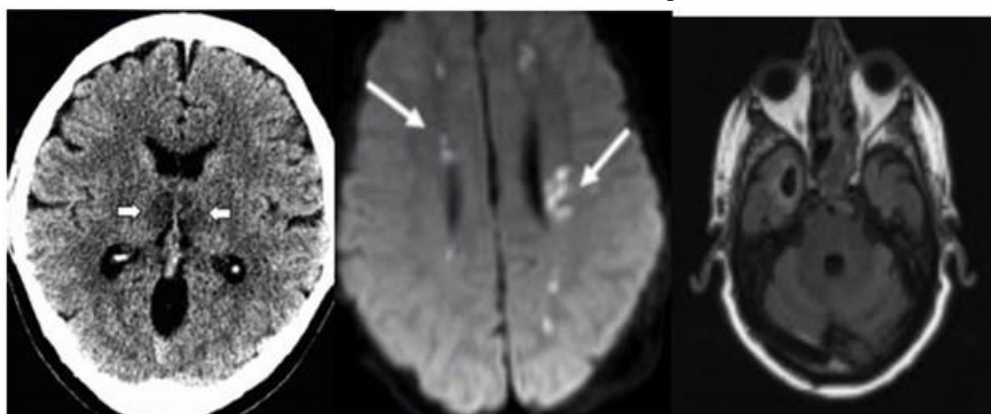


Figure 1: MRI Brain showing hyperintense lesions in the subcortical white matter, thalamus and basal ganglia

5. Conclusion

AHNE can present with neurologic manifestation in COVID-19. This pathology can be characterized by sudden and severe encephalopathy, this case presentation demonstrates that SARS-CoV-2 is a major cause of central nervous system and may manifest as AHNE. The present patient is our very first case of acute onset and cognitive impairments due to SARS-CoV-2 in the absence of both radiological and clinical respiratory manifestations. The reason we present this case is to assist in the early detection and diagnosis of neuro-coronavirus (COVID-2019). In conclusion, clinicians should recognize hemorrhagic necrotizing encephalopathy as a possible complication of COVID-19 with severe cytokine storm.

6. Declarations

Funding: This study has not been funded by anyone, school, organization, or any parties. (Non-applicable).

Conflict of Interest/Competing interests: The authors declare that they have No Conflict of Interest. (applicable)

Complies with ethical standards: Applicable

Consent to participate: Applicable

Consent for publication: Applicable

Availability of data and material: Applicable

Code availability: Non-applicable

Author's contributions: None

References

- Hojyo S, Uchida M, Tanaka K, Hasebe R, Tanaka Y, Murakami M, et al. How COVID-19 induces cytokine storm with high mortality. *Inflammation and Regeneration*. 2020; 40(1).
- Wu X, Wu W, Pan W, Wu L, Liu K, Zhang HL, et al. Acute Necrotizing Encephalopathy: An Underrecognized Clinico-radiologic Disorder. *Mediators of Inflammation*. 2015: 792578.
- DosSantos MF, Devalle S, Aran V. Neuromechanisms of SARS-CoV-2: a review. *Front Neuroanat*. 2020; 14: 37.
- Baig AM, Khaleeq A, Ali U, Syeda H. Evidence of the COVID-19 virus targeting the CNS: tissue distribution, host-virus interaction, and proposed neurotropic mechanisms. *ACS Chem Neurosci*. 2020; 11(7): 995-998.
- Seales D, Greer M. Acute hemorrhagic leukoencephalitis. A successful recovery. *Arch Neurol*. 1991; 48: 1086-1088.
- Adams RD, Cammermeyer J, Dennybrown D. Acute necrotizing hemorrhagic encephalopathy. *J Neuropathol Exp Neurol*. 1949; 8: 1-29.
- Poyiadji N, Shahin G, Noujaim D, Stone M, Patel S, Griffith B, et al. COVID-19-associated acute hemorrhagic necrotizing encephalopathy: imaging features. *Radiology*. 2020; 296:119-120.
- Dixon L, Varley J, Gontsarova A. COVID-19-related acute necrotizing encephalopathy with brain stem involvement in a patient with aplastic anemia. *Neurol Neuroimmunol Neuroinflamm*. 2020; 26: 789.
- Whittaker A, Anson M, Harky A. Neurological manifestations of COVID-19: A systematic review and current update. *Acta Neurol Scand*. 2020; 142(1): 14-22.
- Montalvan V, Lee J, Bueso T. Neurological manifestations of COVID-19 and other coronavirus infections: A systematic review. *Clin Neurol Neurosurg*. 2020; 194: 105921.
- Finsterer J, Stollberger C. Update on the neurology of COVID-19. *J Med Virol*. 2020; 92(11): 2316-2318.
- Desforges M, Le Coupanec A, Dubeau P. Human coronaviruses and other respiratory viruses: Underestimated opportunistic pathogens of the central nervous system? *Viruses*. 2019; 12(1): 14.
- Mori I. Transolfactory neuroinvasion by viruses threatens the human brain. *Acta Virol*. 2015; 59(4): 338-349.
- Virhammar J, Kumlien E, Fallmar D. Acute necrotizing encephalopathy with SARS-CoV-2 RNA confirmed in cerebrospinal fluid. *Neurology*. 2020; 95: 445-449.
- Guo YR, Cao QD, Hong ZS. The origin, transmission and clinical therapies on coronavirus disease 2019 (COVID-19) outbreak – an update on the status. *Mil Med Res*. 2020; 7(1): 11.
- Mishra AK, Lal A, Sahu KK. Letter to the editor regarding “Neurological impact of coronavirus disease (COVID-19): Practical considerations for the neuroscience community” *World Neurosurg*. 2020; 139: 344-354.
- Ghosh R, Dubey S, Finsterer J, Chatterjee S, Ray BK. SARS-CoV-2-associated acute hemorrhagic, necrotizing encephalitis (AHNE) presenting with cognitive impairment in a 44-year-old woman without comorbidities: a case report. *Am J Case Rep*. 2020; 21: 925641.
- Delamarre L, Gollion C, Grouteau G. COVID-19-associated acute necrotizing encephalopathy successfully treated with steroids and polyvalent immunoglobulin with unusual IgG targeting the cerebral fibre network. *J Neurol Neurosurg Psychiatry*. 2020; 91:1004-1006.