

Management of Gastric Varices with BRTO Assisted Endoscopic High-Dose Histoacryl Injection: A Case Report and Review

Wang YL¹, Jin B¹, Han B¹, Xiang L¹ and Zhang WH^{1,*}

¹Liver Cirrhosis Diagnosis and Treatment Center, 5th Medical Center of Chinese PLA General Hospital, Beijing, China

*Corresponding author:

Wen Hui Zhang,
Endoscopy Center Liver Cirrhosis
Diagnosis and Treatment Center
5th Medical Center of Chinese
PLA General Hospital Fengtai District,
Beijing, China,
Tel: 13439712330;
E-mail: zhangwenhui302@163.com

Received: 15 Oct 2020
Accepted: 02 Nov 2020
Published: 07 Nov 2020

Copyright:

©2020 Zhang WH. This is an open access article distributed under the terms of the Creative Commons Attribution License, which permits unrestricted use, distribution, and build upon your work non-commercially.

Citation:

Zhang WH, Management of Gastric Varices with BRTO Assisted Endoscopic High-Dose Histoacryl Injection: A Case Report and Review. *Annals of Clinical and Medical Case Reports*. 2020; 5(1): 1-3.

Keywords:

BRTO; Gastro-renal shunt; Gastric varices; Histoacryl

1. Abstract

1.1. Background: Gastric varices is one of the most serious complication of portal hypertension. Endoscopic injection therapy with Histoacryl is the preferred method in managing gastric variceal bleeding. Iatrogenic ectopic embolism is the most serious complication associated with Histoacryl injection in patients with co-existing gastro-renal shunt. Because of this complication risk, endoscopic injection therapy for the gastric varices co-existing with gastro-renal shunt (GRS) is greatly limited. This paper reports one case of giant gastric varices with a significant gastro-renal shunt being treated with E-BRTO and high-dose Histoacryl.

1.2. Methods: We performed modified balloon-occluded retrograde transvenous obliteration assisted endoscopic Histoacryl injection, which provided a transient occlusion of the GRS during endoscopic high-dose Histoacryl injection. A total of 31.5 mL Histoacryl is injected into the varices by the "sandwich" technique at different locations. Before removing the balloon catheter, angiogram demonstrates the resolution of gastric varices.

1.3. Results: At 1 year, the gastric varices had almost completely disappeared. No embolism or further re-bleeding developed in this patient up to date.

1.4. Conclusions: This case suggests that it is effective and safe with

balloon-occluded retrograde transvenous obliteration followed by endoscopic high-dose Histoacryl injection. This hybrid approach offers another option to the patients with large and high-risk gastric varices with gastro-renal shunt.

2. List of Abbreviations: BRTO: Balloon-occluded Retrograde Transvenous Obliteration; E-BRTO: BRTO Assisted Endoscopic Histoacryl Injection; GV: Gastric Varices; GRS: Gastro-Renal Shunt; MRI: Magnetic Resonance Imaging

3. Case Report

The prevalence of Gastric Varices (GV) in patients with portal hypertension is about 10%~50%, with a bleeding risk 10%~36% and bleeding related mortality risk as high as 25%~55% [1, 2]. Endoscopic injection therapy with Histoacryl (N-butyl-2-cyanoacrylate) is the preferred method in managing acute GV bleeding [3]. For GV, ectopic glue embolism is the most serious complication associated with Histoacryl injection, and this risk increases significantly in patients with co-existing gastro-renal shunt (GRS) [2]. The authors report a case of giant gastric varices with a significant GRS that was treated with a novel method of balloon-occluded retrograde transvenous obliteration (BRTO) assisted endoscopic high-dose Histoacryl injection which we coined the acronym E-BRTO. The modified BRTO provided a transient occlusion of the GRS during endoscopic high dose Histoacryl injection.

A 46-years-old man with end stage liver disease due to hepatitis B presented with a 3 days history of hematemesis and melena. He was admitted to our hospital in July, 2017. Abdominal magnetic resonance imaging (MRI) revealed hepatic cirrhosis, splenomegaly, ascites, GRS, and varices involving the esophagus and gastric fundus (Figure 1a and 1b). Upper endoscopy showed small esophageal varices and giant varices along the lesser curvature and at the gastric fundus (Figure 2a). The gastric varices appeared to be isolated with red markings, suggestive of recent hemorrhage.

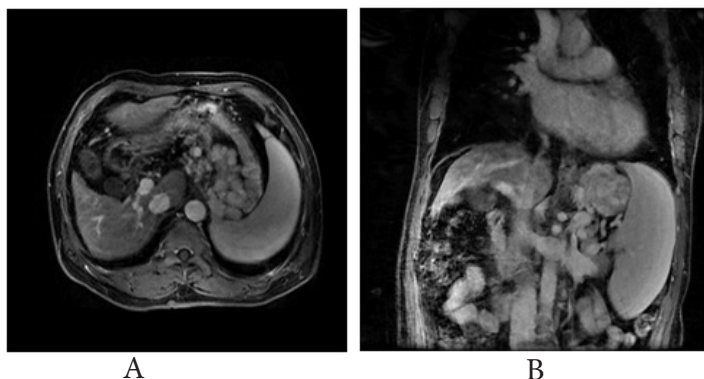


Figure 1: Imaging of gastric varices: a) MRI images showing the giant GV and b) prominent GRS.

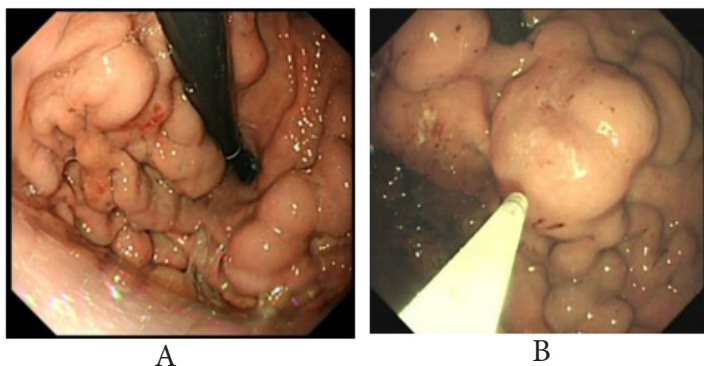


Figure 2: a) Endoscopic images of the giant gastric fundal varices. b) Endoscopic images showing injection of tissue adhesive at different locations.

Hybrid therapy of the GV was performed starting with E-BRTO. Angiography showed the prominent GRS and giant GV (Figure 3a) before therapy. During the combined intervention, a 5.5 French balloon catheter (Fogarty Thru-Lumen Embolectomy Catheter, Edwards Life sciences LLC, USA) was advanced within the GRS through the right femoral vein. After inflating the balloon to occlude the shunt, E-BRTO was performed. High dose Histoacryl (Compont, Beijing Compont Medical Devices Company, Beijing, China) (a total of 31.5 mL or 63 vials), was injected into the GV in 21 aliquots at different locations (Figure 2b). Each injection adopted the "sandwich" technique: 1.5 ml tissue adhesive sandwiched by 2 mL 50% glucose solution depending on the volume of the needle. At each injection location, satisfactory result was judged by hardening of the varices on gentle probing using the needle catheter. At

the end of the intervention, before removing the balloon catheter, a repeat angiogram demonstrated the resolution of GV (Figure 3b). The patient enjoyed an uneventful course after the hybrid therapy.

During routine follow up in one month, upper endoscopy demonstrated no change of esophageal varices, but the size of gastric varices had decreased significantly (Figure 4a). At 1 year, the gastric varices had almost completely disappeared (Figure 4b). No re-bleeding developed up to three years so far.

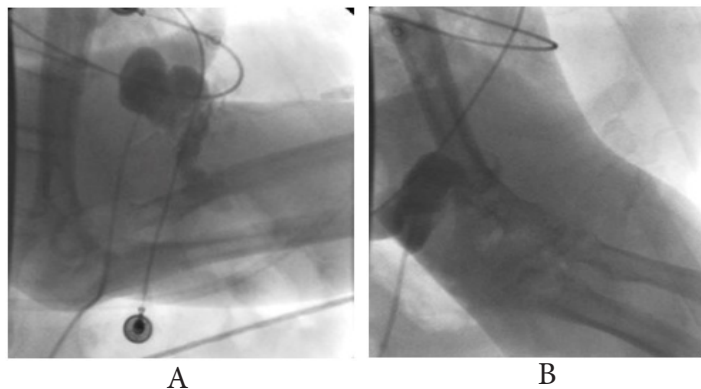


Figure 3: Angiographic images showing: a) The giant gastric varices before endoscopic injection therapy. b) Complete resolution of the gastric varices after injection therapy.

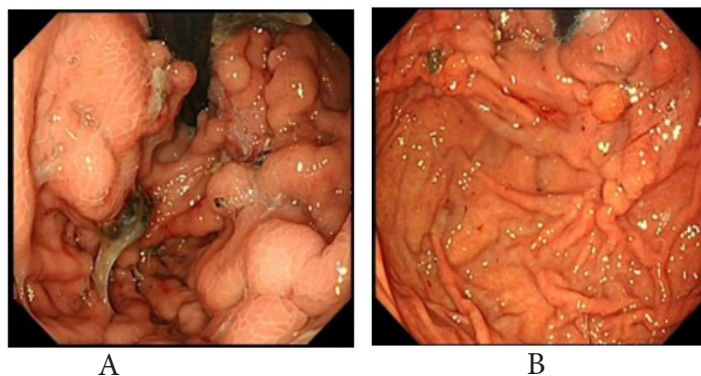


Figure 4: Endoscopic changes of gastric varices before and after treatment: a) Endoscopic images showing the significantly decreased gastric varices at one month. b) Endoscopic images showing the significantly decreased gastric varices at 1 year.

GV is one of the most serious complications of portal hypertension. The prevalence of GV is lower than that of esophageal varices, accounting for about 20%-30% in acute variceal bleeding [1]. When GV bleed, it is usually more severe than esophageal variceal bleeding. With evolution of endoscopic therapy and methods, more attention is paid to the management of acute gastric varices bleeding. Variceal embolization with endoscopic Histoacryl injection has become the preferred method in the treatment of GV [4]. In 1986, Soehendra et al. first reported the endoscopic Histoacryl injection in GV [5]. Histoacryl solidifies after contacting blood after injection into the GV [6]. It is currently the most effective endoscopic method to treat and prevent GV bleeding [7]. However,

ectopic embolism after intravariceal injection occurs in about 5% and is the most serious complication of this treatment modality. This risk is particularly high if the patient has co-existing GRS. In portal hypertension, the most common portal-systemic collateral shunt is the GRS. Because of this complication risk, endoscopic injection therapy for the GV co-existing with GRS is greatly limited [8]. In 1991, Kanagawa et al. first reported BRTO for treatment of gastric varices [9]. Subsequent studies have shown BRTO with concomitant angioembolization is safe and effective in the management of GV with GRS, with the ectopic embolism risk significantly reduced [10]. Unfortunately, expertise with angioembolization through BRTO is not widely available. Furthermore, in the setting of giant GV, endoscopic approach is more easily accessible through direct endoscopic visualization and injection at different locations. To the best of our knowledge, this is the first reported case of GV in combination of GRS being treated with E-BRTO and high-dose Histoacryl injection. Our case demonstrated that E-BRTO with high-dose Histoacryl injection is a feasible, safe and effective alternative procedure to treat GV with GRS.

References

1. Crisan D, Tantau M, Tantau A. Endoscopic Management of Bleeding Gastric Varices-an Updated Overview. *Curr Gastroenterol Rep* 2014; 16(10): 413.
2. Rosemurgy AS, Zervos EE, Clark WC, et al. TIPS versus peritoneovenous shunt in the treatment of medically intractable ascites: A prospective randomized trial. *Ann Surg.* 2004; 239(6): 883-891.
3. EI-Omar EM. Mechanisms of increased acid secretion after eradication of *Helicobacter pylori* infection. *Gut.* 2006; 55(2):144-145.
4. Garcia-Tsao G, Sanyal AJ, Grace ND, et al. Prevention and management of gastroesophageal varices and variceal hemorrhage in cirrhosis. *Hepatology.* 2007; 46(1): 922-938.
5. Soehendra N, Nam VC, Grimm H, Kempeneers I. Endoscopic obliteration of large esophagogastric varices with bucrylate. *Endoscopy.* 1986; 18(1): 25-26.
6. Chuan Kang Tang, Cheng Li Wen, Xiao Bin He, et al. Evaluation of the efficacy of endoscopic tissue adhesive injection in treatment of gastric varices bleeding from liver cirrhosis. *China Journal of Endoscopy.* 2017; 23(2): 81-86.
7. Chinese Society of Hepatology, Chinese Medical Association; Chinese Society of Gastroenterology, Chinese Medical Association; Chinese Society of Endoscopy, Chinese Medical Association. Guidelines for the diagnosis and treatment of esophageal and gastric variceal bleeding in cirrhotic portal hypertension [J]. *J Clin Hepatol* 2016; 32(02):203-219.
8. Park JK, Saab S, Kee ST, Busuttil RW, Kim HJ, Durazo F, et al. Balloon Occluded retrograde transvenous obliteration (BRTO) for treatment of gastric varices: review and Meta-Analysis. *Dig Dis Sci* 2015; 60(6): 1543-1553.
9. H Kanagawa, S Mima, H Kouyama, Mizuo H, Iziri M, Tanabe T, et al. A successfully treated case of fundic varices by retrograde transvenous obliteration with balloon. *Nihon Shokakibyo Gakkai Zasshi* 1991; 88(7): 1459-1462.
10. Qiong Wu, Hua Jiang, Enqiang Linghu, et al. BRTO assisted endoscopic Histoacryl injection in treating gastric varices with gastrosplenic shunt. *Minimally Invasive Therapy & Allied Technologies* 2016; 25(6): 337-344.