

# Adult Longstanding Large Congenital Inguinal Hernia An Unusual Presentation: A Case Report

Rajiv Sonarkar<sup>1</sup>, Ashutosh Babhulkar<sup>2</sup> and Shriniket Sawarkar<sup>1\*</sup>

<sup>1</sup>Associate Professor, Dept of General Surgery, NKPSIMS, Nagpur

<sup>2</sup>Junior Resident, Dept of General Surgery, NKPSIMS, Nagpur

<sup>3</sup>Assistant Professor, Dept of General Surgery, NKPSIMS, Nagpur Dr. Shreyash Khot, Junior Resident, Dept of General Surgery, NKPSIMS, Nagpur

## \*Corresponding Author:

Shriniket Sawarkar,

Assistant Professor, Dept of General Surgery, NKPSIMS, Nagpur Dr. Shreyash Khot, Junior Resident, Dept of General Surgery, NKPSIMS, Nagpur

**Received Date:** 08 Oct 2024

**Accepted Date:** 16 Oct 2024

**Published Date:** 21 Oct 2024

## Citation:

Shriniket Sawarkar. Adult Longstanding Large Congenital Inguinal Hernia An Unusual Presentation: A Case Report. Annals of Clinical and Medical Case Reports 2024.

## 1. Abstract

**1.1. Introduction:** Inguinal hernia is one of the most surgical common diseases. A congenital inguinal hernia is an indirect hernia related to failure of closure of the patent processus vaginalis (PPV) at the deep inguinal ring. Intra-abdominal contents pass within a PPV, through the deep inguinal ring, inguinal canal, superficial inguinal ring and potentially into the scrotum (male) or via the canal of Nuck to the labium (female). [9] But most of the congenital hernias present at an early age, while in this case the patient presented at an age of 65 years.

**1.2. Presentation Of Case:** A 65-year-old male presented with giant right-side inguino-scrotal swelling since birth on clinical examination. Ultrasound study revealed small bowel as the content and no signs of bowel obstruction. He underwent hernia repair. Hernioplasty was performed without any complications. He recovered uneventfully.

**1.3. Discussion:** There are several techniques described in the literature for repair of the inguinal hernias but the surgical techniques of choice rather depend on the defect size the content of the hernia. There is no one gold standard method advised. Congenital hernias mostly present at an early age. Delayed presentation of congenital inguinal hernia is a rare

entity. Hereby reporting a case of unusual and rare presentation of an adult long-standing large congenital inguinal hernia.

**1.4. Conclusion:** Surgical repair for the rare presentations of inguinal hernia can be challenging and require expertise and proper technique selection for repair as recurrence in such cases can be high.

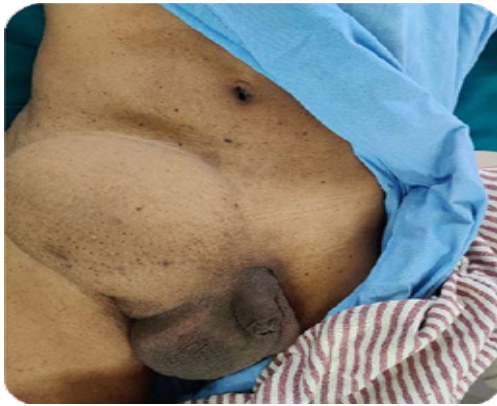## 2. Introduction

Inguinal hernia is one of the most common surgical diseases. The history of inguinal hernia repair can be traced to ancient times and the treatment has evolved, developed and changed since. The most commonly performed surgery now-a-days is Tension free hernia repair. Even though considering the simplicity of the procedure there are many publications of the advances in the hernia repair. The latest trends show laparoscopic hernia repair and use of different types of prosthetic mesh to be becoming popular. An adult long-standing large congenital inguinal hernia, however, is more unusual and significantly challenging in terms of surgical management. No Specific treatment has been suggested as the standard procedure of the management of such uncommon hernias and various hernia repair techniques have been tried and published in various articles and case reports. Thus, choosing a treatment plan is still a dilemma and is a decision to be made by the operating surgeon. This article is a case report of an adult long-standing large congenital inguino- scrotal hernia containing small bowel as the content with no signs of obstruction. This was managed by Open Preperitoneal Mesh Repair (Stoppa Repair).

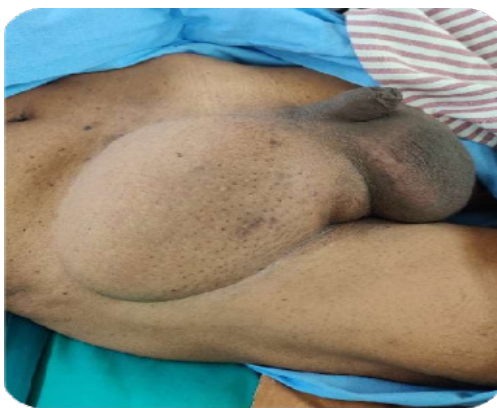## 3. Presentation Of Case

A 65 years old healthy male, Farmer by occupation, came with complaint of swelling in the right-side inguinal region since birth. Patient neglected the complaints till presentation and came for the management now due to the increased discomfort in this daily activity caused due to the swelling. Patient had no other symptoms such as abdominal fullness, nausea, vomiting, constipation or pain in abdomen. Patient had no Comorbidities and had no history of any previous abdominal Surgery. Patient was diagnosed as Right inguinal congenital hernia. Patient underwent an Ultrasound study to reveal small bowel loops contained in hernia sac without any signs of obstruction. (Figure 1-4)

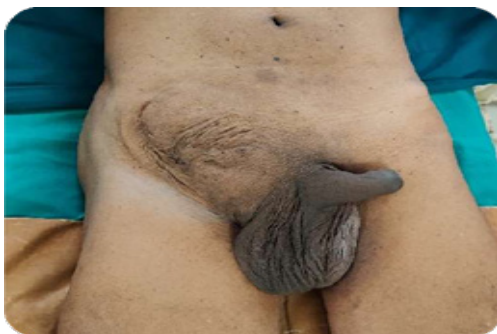**Figure 1:** Giant Right Inguinal Hernia (Pre-Op)



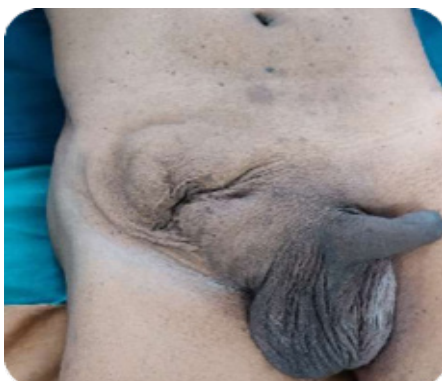**Figure 2:** Giant Right Inguinal Hernia (Pre-Op) (Lateral View)



**Figure 3:** Giant Right Inguinal Hernia (Pre-Op) (After reducing)



**Figure 4:** Giant Right Inguinal Hernia (Pre-Op) (After reducing)



#### 4. Operative steps

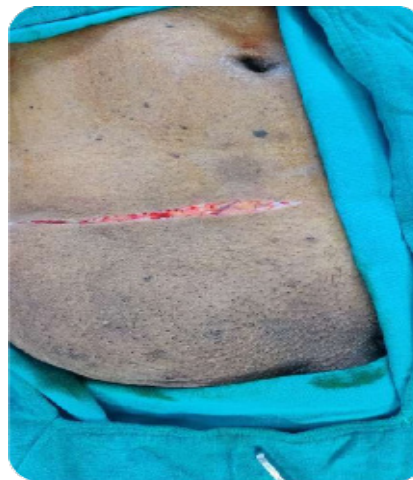##### 4.1. Pre-incision protocol

For the operation, after spinal anaesthesia was administered, Cleaning and Draping was done. Pre-incision antibiotic (Inj. Ceftriaxone 1gm) was given.

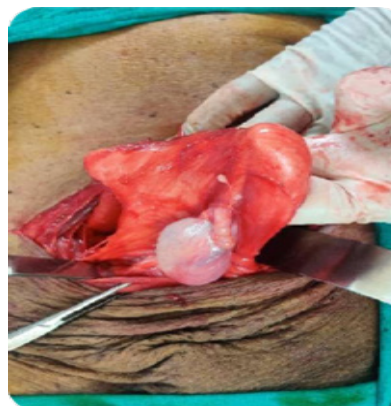##### 4.2. Dissection

Transverse incision in the right inguinal area was marked with skin pen and made. Incision deepened up to the hernial sac. Adhesiolysis done releasing the adhesions to the Anterior Abdominal wall and Sac. Hernia sac was dissected and separated from spermatic cord. The Dissection was done extending medially beyond the midline and laterally up to the psoas muscle. (Figure 5-6)

**Figure 5:** Transverse Right Inguinal Incision



**Figure 6:** Hernial Sac along with Right Testis



##### 4.3. Dealing with peritoneal tear

After the hernia sac was opened, ileum was found inside the hernia sac. The contents of the sac were reduced into the abdominal cavity. Peritoneal tear Repair was done with Vicryl 2-0 Sutures and was reduced in to the abdominal cavity.

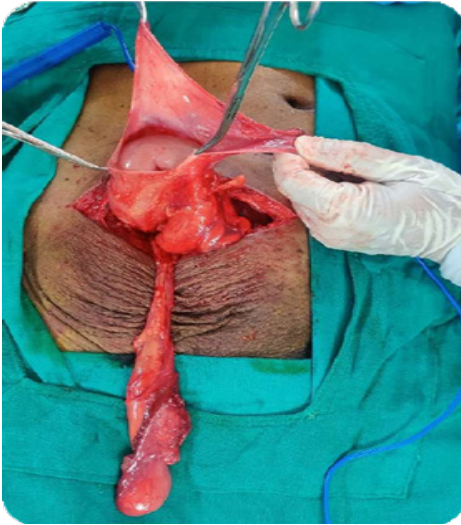


# Annals of Clinical and Medical Case Reports

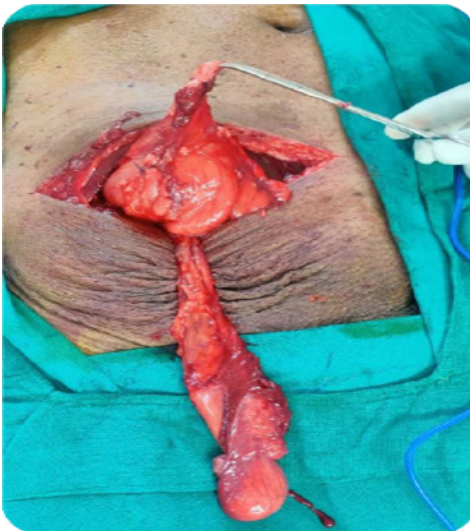## 4.4. Dealing with large defect in the abdominal wall

The muscles of the abdominal wall were found to be deficient in the right iliac fossa. A defect of size approximately 10x8cms was seen in the abdominal wall. Decision to do Stoppa Repair was taken. (Figure 7,8)

**Figure 7:** Hernial Sac (opened) along with Right Testis



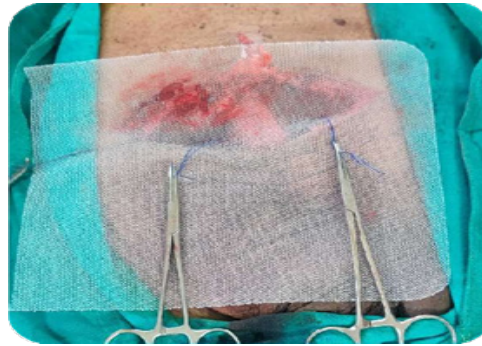**Figure 8:** Closed Peritoneal Tear along with Right Testis



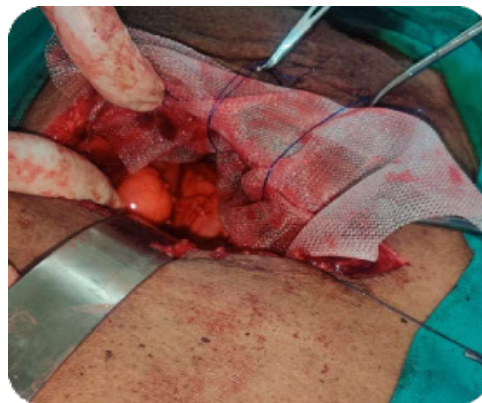
## 5. Placement of Mesh

Monofilament Polypropylene Mesh of size 15cms x 30xms was cut into appropriate size and was placed extending from Right psoas muscle laterally to beyond the midline medially. 3 sutures were taken, one at the pubic symphysis, second at the right ilio-pectineal ligament and the third at the right Psoas Muscle for fixing the mesh with Prolene no 1. Mesh was fixed tension free in the preperitoneal space. (Figure 9,10)

**Figure 9:** Placement of Mesh



**Figure 10:** Placement of Mesh

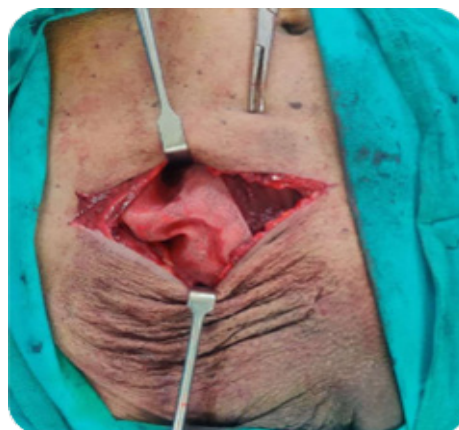

## 5.1. The drain and closure

A Negative Suction drain (16 Fr) was placed superficial to the mesh. External oblique was closed using Polypropylene (Prolene) Sutures. Subcutaneous wound closed using Vicryl 2-0. Skin Closure was done using Ethylone 2-0. (Figure 11,12)

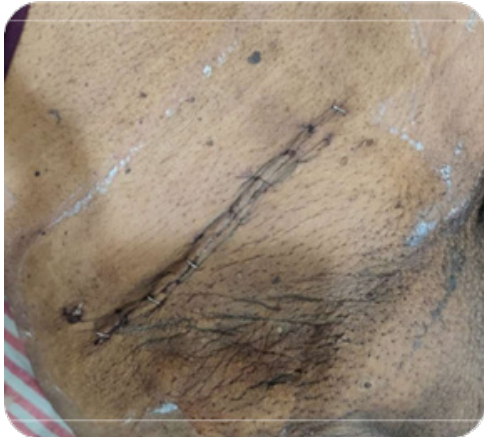- The drain was removed on post-op day 2. Patient's post-op period was uneventful and was discharged on post-op day 4.
- Suture line was healthy with no Gape or Discharge on post-op day 10 and Suture removal was done.

**Figure 11:** Placement of Mesh



# Annals of Clinical and Medical Case Reports

**Figure 12:** Wound Closure



## 6. Discussion

Hernia is among the most common surgical diseases today. Inguinal Hernioplasty is amongst the most commonly performed surgeries. Giant Inguinal hernias are rather rare but the surgical management depends firstly on the size of the defect and the content of the hernia. The obstructed and strangulated hernias need to be treated in emergency. Reducible hernias with no obstructive signs can be treated electively. Despite of various competent methods, technical aspects of hernia repair continue to evolve [2]. In 1958 Usher et al developed polypropylene mesh, Marlex, and used it in large hernia repair. The use of mesh significantly reduced the incidence of recurrence following repair. However, this is not without complication, the most common being infection and migration of mesh [1, 3]. With use of presently available dual mesh, made up of expanded PTFE with impregnated silver carbonate and chlorhexidine and composite mesh which is made up of more than one type of material, incidence of bowel erosion and mesh migration have reduced [1]. Stoppa repair provides certain inherent advantages to the surgeon. [4, 5, 6]

- tension free repair
- This procedure avoids reopening through distorted anatomy in cases of recurrent/multi recurrent hernias
- Exploits Pascal's principle to hold the mesh in place suturelessly
- Reduces the risk of nerve injury, neuralgia, orchitis, testicular atrophy and chronic pain. These as stated by Stoppa, are potential medico legal complications which are frequent in other inguinal herniorrhaphies
- This space is a virgin space typically intact during repair of recurrent hernias which greatly facilitates the procedure.

In our case, the hernia was congenital which was neglected and presented at 60 years of age. We preferred Stoppa repair due to the large defect in abdominal wall. Thus a large 15x30cms mesh was fixed with Prolene no 1 as with the large defect there was an increased risk of mesh migration and recurrence. [7,8] A Negative Suction drain was kept to avoid Seroma formation and negative suction also plays some role in keeping the mesh in place. Patient was followed up and did not complain of any pain at

surgical site or any recurrence. This case demonstrates correction of large Inguinal hernia with Stoppa Repair with no post operative complications.

## 7. Conclusion

Giant inguinal hernia is an uncommon condition defined as an hernial sac extending below mid-inner thigh in the standing position. Surgical repair is challenging and correlated with significant morbidity and mortality due to increased intra-abdominal pressure. We categorize giant inguinal hernia into three types, depending on its location and choice of operations. Surgical techniques, in addition to forced reduction with simple hernioplasty, are resection of contents and intra-abdominal volume increase procedure, combined with repair of hernia. The majority of publications on the subject are case reports and small case series, making it difficult to compare between the procedures. Application of appropriate technique for the individual patients is the key to success treatment and that is more important than strict adherence to anyone technique.

## References

1. Andrew G. Harrell, Yuri W. Novitsky. *Shakelford's Surgery of the alimentary tract*. Sixth edition; Saunders. Vol. 1.p.671-687.
2. Patrick J. Javid PJ, David C. Brooks. *Maingot's Abdominal Operations*. Eleventh edition; Mc Graw Hills. Vol.1 p.133-137.
3. Graziano - M. Santangelo et al. Mesh erosion into the bladder: complication by hernia repair. *Acta Chirurgica Mediterranea*, 2007, 23: p.127-128.
4. Stoppa RE. Giant prosthesis for replacement of visceral sac in the repair of groin and incisional hernia. In Fisher JE, Bland KI. *Master's of Surgery*. 5th edition, Lippincott Williams and Wilkin's. 2007;1924- 30.
5. Stopp RE. The preperitoneal approach and prosthetic repair of groin hernias. In: Nyhus LM, Condon RE. *Hernia*. 4th ed. Philadelphia. J. B. Lippincott. 1995;201-10.
6. Nyhus LM, Condon RE. Clinical experiences with preperitoneal hernia repair for all types of hernia of the groin. *Am J Surg*. 1990; 100:234.
7. De Santis L, Frigo F, Bruttocao A, Terranova O. Pathophysiology of giant incisional hernias with loss of abdominal wall substance. *Acta Biomed*. 2003;74 Suppl 2: 34-37. (Pubmed).
8. Pailler JL, Lalchelle Coadou A, Dupont-Bierre E. Incisional hernia of the anterior abdominal wall. Pathophysiology, etiology and prosthetic repair techniques. *Ann Chir Plast Esthet*. 1999 Aug;44(4):p.313- 324.(Pubmed)
9. Khoo AK, Cleeve SJ. Congenital inguinal hernia, hydrocoele and undescended testis. *Surgery (Oxford)*. 2016 May 1;34(5):226-31.