

Intraosseous Access Under Adverse Circumstances

Schummer W*

Department of Anesthesiology and Intensive Care Medicine, Friedrich-Schiller University of Jena, Jena, Germany

Volume 2 Issue 4- 2020

Received Date: 11 Jan 2020

Accepted Date: 24 Jan 2020

Published Date: 28 Jan 2020

This presentation displays the case of a 5-year old child suffering from severe pneumonia. No antimicrobial drugs had been given in the pre hospital setting so far. The boy lived in a remote home caring for children with innate, severely disabling musculoskeletal disorders. The rescue services were called in the morning due to the apparently life-threatening condition of the patient. In order to cover the medical emergency as quick as possible, a rescue helicopter was sent. When the team arrived at the scene, they found a tachypneic ($>35/\text{min}$), hypoxic ($\text{SpO}_2 < 80\%$) boy, merely responding to pain. Additionally, hemodynamics were massively impaired (pulse rate $> 150/\text{min}$, systolic blood pressure 60 mmHg). Via a Hudson facemask, oxygen with 15 l/min was administered. There was no chance to gain peripheral vascular access and after two futile attempts the doctor decided to switch to an intraosseous approach. The EZ-IO¹ intraosseous vascular access system is part of the regular equipment of this rescue helicopter.

Access was gained at first attempt at the right tibia (Fig 1). Hemodynamics could be stabilized (sinus rhythm 120/min, blood pressure 90/50 mmHg) after 1 l of crystalloids (given in a 20/20/20cc/kg manner) and under norepinephrine 0.2 $\mu\text{g}/\text{kg}/\text{min}$ (forced by syringe driver to the bone). While oxygen saturation increased to 91% under oxygen insufflations the patient regained consciousness and opened his eyes to verbal stimulation. The team discussed the situation and the possible options.

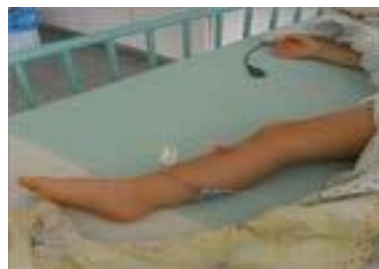

Figure 1: Intraosseous access outside of recommended site

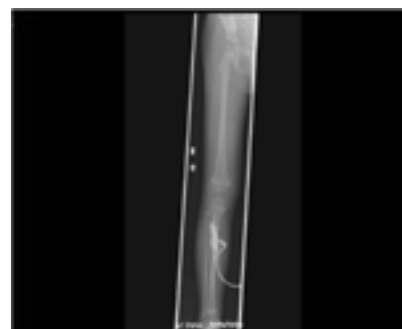

Figure 2: Contrast-enhanced X-ray of right leg: vascular spread

*Corresponding Author (s): Wolfram Schummer, Department of Anesthesiology and Intensive Care Medicine, Friedrich-Schiller University of Jena, Jena, Germany, E-mail: cwsm.schummer@gmx.de

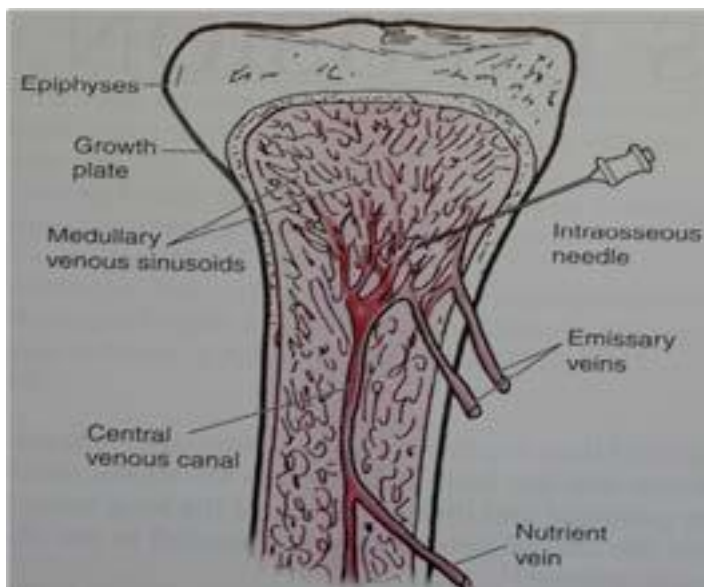


Figure 3: Blood supply of long bone (according to Gray's Anatomy)

With respect to potentially challenging airway (cranio-facial abnormalities) and the short flight time to the hospital the decision was made to conduct intubation in a safer setting.

Accordingly, the intensive care unit was informed about the special circumstances in order to get prepared. Then the patient was flown to the hospital and was rushed directly to the intensive care unit where he was immediately intubated via fiberoptic bronchoscope. Mechanical ventilation was started on FiO_2 1.0 and PEEP of 12 cmH_2O to reach oxygen saturations $>90\%$. Concurrently, central venous access was gained via the left subclavian vein and arterial access via the left radial artery. Several sets of blood cultures were drawn and a BAL was performed. The specimens were sent for analysis, empiric antimicrobial therapy was started with piperacillin/tazobactam. However, the clinical situation could not be consolidated and the patient went progressively into multiple organ failure. In accordance with the parents life-sustaining measures were suspended on day seven and the patient passed away peacefully.

After initial management, a contrast enhanced X-ray of the right leg had been performed because the site for intraosseous access did not correspond exactly to the recommended one (Fig 2). Tibial fracture, lesion to the growth zone and extravasation could be excluded. Blood supply of a long bone drain to venous channels which leave through all surfaces not covered by articular cartilage [1]. The blood flow through the shafts of long bones is mainly centrifugal (Fig 3). Intraosseous access takes advantage of this characteristic.

Learning points

- Intraosseous access (IO) is invaluable especially when conventional techniques to gain vascular access fail.
- The ease of IO is impressive, no matter whether the recommended site is met or not.
- IO is used as 'central' access for children regularly, however it does require syringe drivers to force the inotrope in under pressure to the bone. Applying vasoactive drugs by a drip process would not necessarily provide a regular delivery. In the meanwhile, we have noted that even with syringe drivers a certain amount of delivery fade occurs with time.
- Intraosseous access can be life-saving in extreme emergencies where immediate delivery of medications and fluids is urgent [2-4].

References

1. Standring S. (ed.) Chapter 6 'Neurovascular supply of bone' in Gray's Anatomy 39th ed. 2005. pp 93-97.
2. Helm M, Gries A, Fischer S, Hauke J, Lampl L. Invasive techniques in emergency medicine. III. Intraosseous puncture-an alternative vascular access in paediatric emergencies. *Anaesthesist*. 2005; 54: 49-56.
3. Weiss M, Gächter-Angehrn J, Neuhaus D. Intraossäre Infusionstechnik. *Notfall Rettungsmed* 2007; 10: 99-116.
4. Paxton JH, Knuth TE, Klausner HA. Proximal Humerus Intraosseous Infusion: A Preferred Emergency Venous Access. *J Trauma*. 2009; 67: 606-611.